

Rapid Recovery from COVID-19 Respiratory Failure with comorbidity in 21 patients treated with Vasoactive Intestinal Peptide

J Georges Youssef, MD ^{1,2}

Jonathan C. Javitt, MD, MPH ^{3,4}

Mukhtar Al-Saadi, MD, EdD ²

Faisal Zahiruddin, DO ²

Sarah Beshay, MD ²

Mohammad Z. Bittar, MD ²

Author Affiliations:

1. Houston Methodist Pulmonary Transplant Center, Houston Methodist Research Institute, Houston Methodist Hospital, Houston, Texas, USA
2. Department of Academic Pulmonology, Houston Methodist Hospital, Houston, Texas
3. NeuroRx, Inc. Wilmington, DE
4. Johns Hopkins University, Baltimore, MD

Keywords

Vasoactive Intestinal Peptide, VIP, SARS-CoV-2, COVID-19, Acute Respiratory Distress Syndrome, ARDS, Acute Lung Injury, ALI, surfactant, Alveolar Type II

Word Count: 2250

Correspondence to: jjavitt@jhu.edu

Funding: Research support was provided by the Cavendish Impact Foundation and Princeton Alumni Angels. Clinical trial funding was provided by Relief Therapeutics Holdings, AG, Geneva and NeuroRx, Inc.

Disclosure: Author JCJ is employed by NeuroRx, Inc., a pharmaceutical company that is currently conducting clinical trials of RLF-100 in patients with COVID-19 and serves as an officer of Relief Therapeutics.

Abstract

Background: Vasoactive Intestinal Peptide (VIP) is known to bind to and protect Alveolar Type II cells by blocking replication of the SARS-CoV-2 virus, inhibiting cytokine synthesis, preventing cytopathy, and upregulating surfactant production. RLF-100 (Aviptadil), a synthetic form of Vasoactive Intestinal Peptide (VIP) has been granted Fast Track Designation for treating Critical COVID-19 with Respiratory Failure and is currently in phase 2/3 placebo-controlled trials. FDA has granted Emergency Use IND and Expanded Access Protocol approval for the use of RLF-100 in patients whose comorbidities render them ineligible for inclusion in the ongoing pivotal trial.

Methods: Case series of the first 21 consecutive patients with Acute Respiratory Failure in Critical COVID-19 and multiple co-morbidities, treated with three successive 12-hour infusions of intravenous Aviptadil at 50/100/150 pmol/kg/hr. Sixteen patients were treated with mechanical ventilation at time of enrollment and five with extracorporeal membrane oxygenation (ECMO) in addition to mechanical ventilation.

Results: Median patient follow-up time is 21 days. So far, 19 of 21 patients have survived. One death was due to COVID-related multisystem organ failure and the other to an underlying and unrelated encephalopathy. Improved radiographic appearance of typical “ground glass” COVID-19 features to varying degrees is seen in both lungs of 17 patients and in one lung of 2 patients. A mean 292% increase in PaO₂:FiO₂ ratio was seen during the time patients were on ventilation. Improvement in blood oxygenation is seen in all patients, with complete remission from respiratory failure in 9 patients and ongoing improvement in 10. Seven patients were discharged from the hospital, 7 have been sent to intermediate acute care, and 5 require ongoing intensive care. Three of 5 patients on extracorporeal membrane oxygenation (ECMO) prior to treatment with VIP have been decannulated and two have been discharged to home. A 75% (95% CI±3%: P<.001) reduction in IL-6 was seen with corresponding decrease in C-reactive protein. A median 4 point reduction in the NIAID Ordinal Scale was observed (P<.01).

Comment: The short term outcomes in these 21 patients represent a dramatic response in patients who are excluded from all other trials of COVID therapeutics. Improvement in radiographic appearance, oxygenation requirement, and inflammatory markers is consistent with *in vitro* evidence of direct anti-viral effect. A phase 2/3 placebo-controlled trial in patients with Critical COVID-19 and respiratory failure is ongoing.

Background

Vasoactive Intestinal Peptide (VIP) is shown to block replication of the SARS-CoV-2 virus in human pulmonary epithelial cells and monocytes, while also demonstrating clinical improvement on radiographic and laboratory parameters.¹ In addition to its antiviral effect, VIP protects the Alveolar Type II (ATII) cell by upregulating surfactant production, blocking apoptosis, and blocking cytokine effects. *In vitro* evidence suggests that human monocytes treated with VIP secrete soluble agents that further protect ATII cells via a “bystander effect”.

SamiVir™ (Aviptadil), a synthetic form of Vasoactive Intestinal Peptide (VIP) has been granted Fast Track Designation and is currently in phase 2/3 placebo-controlled trials (NCT04311697). FDA has granted Emergency Use IND and Expanded Access Protocol approval NCT04453839 for the use of RLF-100 in patients whose comorbidities render them ineligible for inclusion in the ongoing pivotal trial. These comorbidities, predictive of poor outcomes in COVID-19, were deemed to be sufficiently rare that enrollment could not adequately be balanced within the structure of the randomized trial. That is particularly true of patients whose pulmonary function has deteriorated to the point of requiring Extracorporeal Membrane Oxygenation (ECMO) to sustain life.

The drug is named for Prof. Sami Said, who discovered VIP in 1970.² Over 50 years of research VIP has been shown to protect the lung against a broad array of caustic, immune, and infectious injuries^{3,4,5,6} through its binding to the VPAC₁ receptor of the Alveolar Type II cell. This is the same pulmonary cell to which the SARS-CoV-2 virus binds via the ACE2 receptor⁷. VIP by intravenous administration has previously demonstrated effectiveness in treating ARDS related to sepsis.⁸ Promising results have been shown with inhaled administration in treating sarcoid⁹, and pulmonary hypertension^{10,11}.

Patients and Methods

Human subjects protection was overseen by Advarra IRB, the Institutional Review Board (IRB) of the Houston Methodist Hospital, and an independent Data Monitoring Committee. Twenty one patients with PCR-proven COVID-19 and respiratory failure were screened for NCT04311697 and deemed ineligible on the basis of exclusionary comorbidity (see clinicaltrials.gov). On that basis, they were offered treatment with aviptadil, initially under FDA Emergency Use IND, which FDA subsequently converted to an intermediate population size Expanded Access Protocol (EAP). Under Emergency Use IND, FDA was contacted prior to the treatment of each patient and approved the use of intravenous RLF-100. Under EAP, treatment was administered per FDA-approved protocol. Investigational product was donated for expanded access use by NeuroRx, Inc. (Wilmington, DE).

The first 21 consecutive patients enrolled as above are described in this report. Sixteen were treated with mechanical ventilation at time of enrollment and 5 with mechanical ventilation plus ECMO. Each of the patients enrolled in this emergency use program was experiencing clinical deterioration at the time of enrollment despite receiving maximal intensive care. The median age of patients was 71 (Interquartile range [IQR] = 25 years) and there were 3 male and 3 female patients (Table 1). Each of the patients enrolled in this emergency use program was showing signs of clinical deterioration despite receiving maximal intensive care for COVID-19 related respiratory failure at the Houston Methodist Hospital. Each patient received three 12-hour intravenous infusions of Aviptadil at graduating doses of 50, 100, and 150 pmol/kg/hr. One patient (Patient 10) received only the first two infusions as he developed hemorrhagic shock complicating a chest tube insertion for a spontaneous pneumothorax and did not receive the third dose. Patients received background treatment with remdesivir, tocilizumab, and convalescent plasma as available and per the treating physician discretion. However, supply shortages of these agents were such that only Patient 1 received convalescent plasma before Aviptadil with no clinical improvement following treatment.

Hypothesis testing was by paired t-test.

Clinical Results

Median patient follow-up time is 21 days. So far, 19 of 21 patients have survived. One death was due to COVID-related multisystem organ failure and the other to an underlying and unrelated encephalopathy.

Twenty of 21 patients demonstrated improvement in blood oxygenation (fig 1). The improvement was similar in ventilated patients versus those treated with ECMO. Available data from blood gases showed stark increases in PaO₂:FiO₂ ratio after the 2nd dose (Median increase = 92.5, IQR = 74) and at 24 hours after the 3rd dose (Median increase over baseline 84.5, IQR = 110). No patient showed deterioration of oxygenation below baseline during subsequent measurements.

Radiographic evidence (figure 2) on all patients is included in the online supplementary material. In all cases, clearing of the “ground glass” parenchymal changes associated with COVID-19 pneumonitis was apparent and

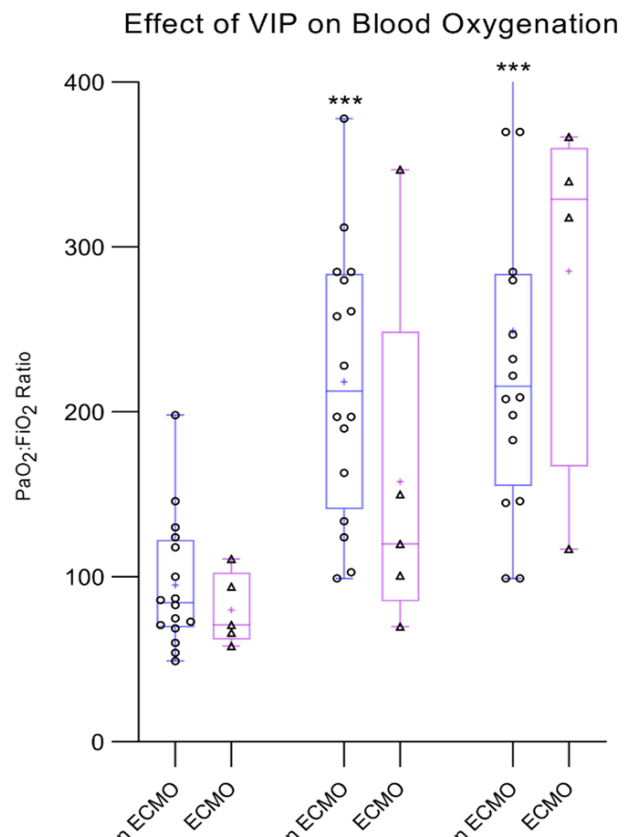


Figure 1: Effect of VIP on blood oxygenation. Substantial improvement in PaO₂:FiO₂ ratio can be seen in 20 of 21 patients (P<.001). Similar trends are seen in those treated with (n=5) and without ECMO (n=16)

was noted by the radiologists who read the chest x-rays. Quantitative analysis of radiographic changes will be the subject of a future report.

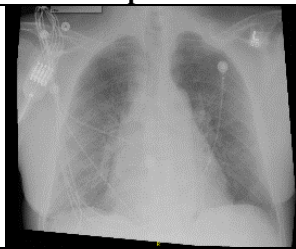
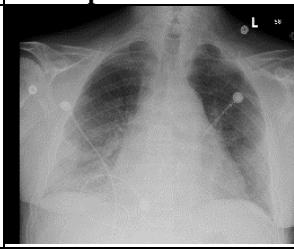
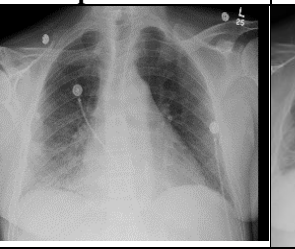

Patient 2	Before Aviptadil	24-hr post 3rd Dose	48-hr post 3rd Dose	2 weeks s/p Aviptadil
Portable Chest X-Ray				
PaO2:FiO2	146	146	285.19	
SaO2	98	89	95	97
Ventilation	HFLNC 30 L/min, FiO2 50%	6 L/min	2 L/min	2 L/min

Figure 2 (Representative Radiographic Appearance and blood oxygen saturation before and after treatment. In 20 of 21 patients partial or complete resolution of “ground glass” parenchymal changes typical of COVID-19 was ascertained by radiologist review. See online supplement for radiographic appearance of all patients.

A laboratory panel of inflammatory markers, including LDH, troponin, C-reactive protein, ferritin, D-Dimer, and interleukin 6 was obtained prior to and post treatment with aviptadil (figure 3). In all patients, improvement can be seen on each of the inflammatory markers. The largest average percent decrease was seen in C-reactive protein (76% ±3%) and interleukin 6 (75% ±3%). No patient demonstrated an increase in any of the inflammatory markers.

Hospital course and adverse events. The time to resolution of respiratory failure ranged from 3 – 20 days (mean 10.5) and time to ICU discharge ranged from 1 – 21 days (mean 8.1) in the 10 of 21 patients so far discharged from intensive care (Table 2). Clinical narratives are included in the online supplementary material. There were various complications in hospital courses following completion of the Aviptadil regimen (Table 1) as would be expected in patients with this degree of comorbidity. For instance, patient 2 was scheduled for discharge to home 3 days following completion of treatment but fell in the hospital and suffered a retroperitoneal bleed which led to a subsequent 10 day course of inpatient care. Patient 4, who was about to be treated with extracorporeal membrane oxygenation (ECMO) successfully demonstrated improvement in respiratory distress but developed line sepsis with confirmed *S. Epidermidis* which has led to chronic respiratory distress and continued ventilation. Patient 4’s hospital course was complicated by an apical pneumothorax attributed to prone positioning that occurred 24 hours after completing Aviptadil therapy. The pneumothorax spontaneously resolved after discontinuation of prone positioning and no chest tube was required. Vasopressors were administered for continued acidosis and hypotension and were subsequently weaned. The patient was started on inhaled nitric oxide and CRRT. The patient had slow clinical and radiologic improvement but remains in the ICU requiring ventilatory support.

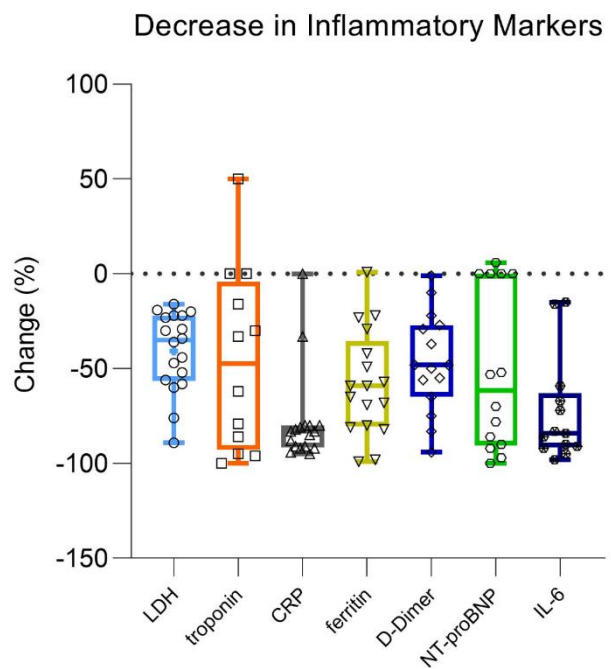


Figure 3: Decrease in inflammatory markers as a percent change from pretreatment value. The decrease is both clinically and statistically significant (P<.001)

No drug-related Serious Adverse Events (SAEs) including mortality were recorded. Only one patient developed a drug-related (non-serious) adverse event. Hypotension was seen in two patients that was successfully managed with pressors and did not require cessation of infusion. Diarrhea was seen in 4 patients, consistent with the known metabolic effects of VIP.

Clinically and statistically significant improvement in the WHO Ordinal Scale (figure 4), where zero represents discharge to home with no need for further therapy and 10 represents death can be seen in both ventilated and ECMO-treated patients. The median improvement was 4 points (mean 2.5 points; $p < 0.001$)

Discussion

This is the first reported treatment of Acute Respiratory Failure in patients with Critical COVID-19 using Vasoactive Intestinal Peptide (Aviptadil). The twenty-one patients in this report had serious comorbidities that made them ineligible for participation in the ongoing FDA phase 2/3 pivotal study of RLF-100 (aviptadil) in the treatment of COVID-19 respiratory failure. All six patients demonstrated rapid clinical improvement in both blood oxygenation and radiographic features, although respiratory failure persists in 8 patients. The substantial decrease in inflammatory markers seen in all patients, particularly in ferritin, D-Dimer, and IL6 which are increasingly associated with poor prognosis in COVID-19 suggests that the radiographic and oxygenation improvement seen in these patients may be tied to an etiologic effect of Aviptadil. The fact that all patients have, so far, survived is highly unexpected in COVID-19 patients with this degree of comorbidity and the fact that four of the ten have been discharged from acute care is equally remarkable. Patient 3 remains on mechanical ventilation not because of oxygenation failure but rather because of respiratory muscle weakness. Patient 4 was scheduled for extubation when a pneumothorax developed requiring additional ventilatory support.

This is the second similarly case series in which aviptadil has been associated with a remarkable degree of improvement in patients with Acute Respiratory Distress. In the 2005 time frame, 8 patients with sepsis-related Acute Respiratory Distress Syndrome were treated with the same intravenous protocol.¹² All 8 patients demonstrated clinical improvement, 7 were discharged from intensive care and life support was terminated in the 8th for neurologic, rather than pulmonary reasons. Although the case series was not reported until recently because of the retirement and subsequent demise of the senior author, the clinical care was managed and results recorded by one of our authorship (JGY). Similar clearing of pneumonitis with aviptadil (delivered by nebulizer) was recently reported in a patient with checkpoint inhibitor pneumonitis.¹³

Early COVID-19 lung injury is characterized by a remarkable degree of hypoxemia in the absence of overwhelming pneumonia, suggesting a primary injury to the pulmonary gas-exchange mechanism.

Although named (or mis-named) for the gut where it was first isolated, 70% of VIP is localized to the lung and binds primarily to Alveolar Type II cells (ATII) cells via VPAC₁.¹⁴ ATII cells comprise only 5% of the pulmonary epithelium but are critical to surfactant production and recycling as well as the maintenance of type I epithelial cells. The SARS-CoV-2 virus specifically attacks ATII via their ACE2 surface receptors and does not enter the Type I

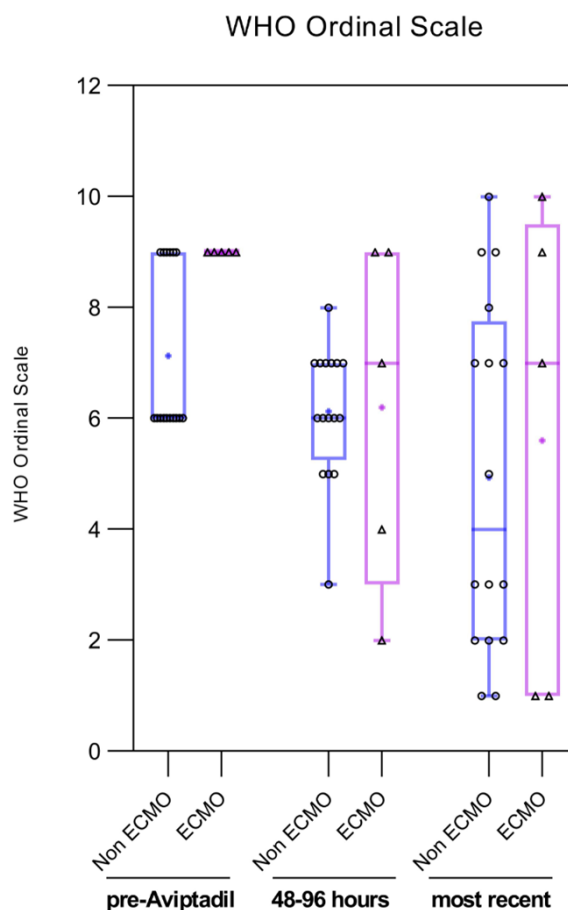


Figure 4: Change in WHO ordinal severity scale in patients treated with ventilation alone (n=16) vs. those treated with ECMO (n=5). Statistically significant improvement can be seen overall ($P < 0.001$) and is similar in those treated with ventilation alone vs. those treated with ECMO

pneumocyte.¹⁵ VIP preserves the function of lung allografts and may have been particularly beneficial in this patient who was suffering active graft rejection.^{16,17}

Unlike synthetic anti-cytokines, such as anti-IL6 drugs, VIP is shown to have a specific role in preserving surfactant production in the lung.^{18,19,20,21} Accordingly, VIP and longer acting modifications of VIP have been proposed in the past as respiratory therapeutics²². Li demonstrated in rat lung explants that VIP increased the incorporation of methylcholine into phosphatidylcholine -- the major component of the pulmonary surfactants -- by enhancing the activity of the enzyme choline-phosphate cytidyltransferase¹⁶. VIP upregulates C-Fos protein expression in cultured type II alveolar cells, which is instrumental in promoting synthesis of pulmonary surfactant phospholipids¹⁷ and induces surfactant protein A expression.

Conclusion:

The significant clinical improvement seen in these 21 patients treated with intravenous RLF-100 (Aviptadil), is consistent with the finding that VIP not only blocks viral replication in the pulmonary epithelium but creates a “bystander effect” whereby nearby monocytes secrete soluble antiviral agents to further protect ATII cells, blocks cytokine storm, and improves oxygenation in a lung that is under attack by the SARS-CoV-2 virus. This highly specific role of VIP in the lung may be key to combating the lethal effects of SARS-CoV-2 infection. A randomized prospective trial is underway, which will attempt to demonstrate that intravenous RLF-100 improves survival, oxygenation, and clinical course of Critical COVID-19 with respiratory failure. The independent Data Monitoring Committee of that trial has conducted the first unblinded look at the study data and identified no safety signals. Moreover, the DMC has determined that the study is not futile in its objective to identify a statistically significant difference between aviptadil and placebo in remission from COVID-19 respiratory failure.

The patients reported here were deemed too ill to be randomized in the ongoing phase 2/3 clinical trial of RLF-100 for treatment of Critical COVID-19. Most notably, four of the patients included in this series were treated with ECMO, an end-stage treatment known for mortality of at least 31%, with 53% of patients still on ECMO after 3 weeks.²³ Need for ECMO represents a treatment-failure event in the phase 2/3 randomized controlled trial of aviptadil.

The clinical course of the patients in this study, with some having demonstrated rapid clinical recovery and discharge to home while others continue to improve more slowly is striking for the consistency of improvement on radiographic changes, blood levels of inflammatory markers, and improvement in blood oxygenation. The radiographic improvement seen in these patients, is highly atypical for COVID-19 and suggests that Aviptadil may be effective in treating COVID-19 and has substantial potential to demonstrate efficacy in adequately-controlled trials.

References

- ¹ Temerozo JR, Sacramenta Q, Fintelman-Rodrigues N, et. al. The neuropeptides VIP and PACAP inhibit SARS-CoV-2 replication in monocytes and lung epithelial cells, decrease the production of proinflammatory cytokines, and VIP levels are associated with survival in severe Covid-19 patients doi: <https://doi.org/10.1101/2020.07.25.220806>
- ² Said SI, Mutt V. Potent peripheral and splanchnic vasodilator peptide from normal gut. *Nature*. 1970; 225: 863-864.
- ³ Said SI. Vasoactive intestinal peptide in the lung. *Ann NY Acad Sci* 1988;527:450-464
- ⁴ Said SI. VIP as a modulatory of lung inflammation and airway constriction *Am Rev Respir Dis* 1991;143:S22-S24.
- ⁵ Said SI, Dickman KG. Pathways of inflammation and cell death in the lung: modulation by vasoactive intestinal peptide. *Regul. Pept.* 2000;93:21-29
- ⁶ Javitt JC. Perspective: The potential role of vasoactive intestinal peptide in treating COVID-19. *Authorea* May 13, 2020 DOI: [10.22541/au.158940764.42332418](https://doi.org/10.22541/au.158940764.42332418)
- ⁷ Mason R. Pathogenesis of COVID-19 from a cell biologic perspective. *Eur Respir J*. April 9 Epub ahead of print. <https://www.ncbi.nlm.nih.gov/pmc/articles/PMC7144160/>
- ⁸ Youssef JG, Said S, Youssef G, Javitt MJ, Javitt JC. Vasoactive Intestinal Peptide in the treatment of Acute Respiratory Distress Syndrome. *Lancet* 2020, under review.
- ⁹ Prasse A, Zissel G, Lützen N, Schupp J, Schmiedlin R, Gonzalez-Rey E, Rensing-Ehl A, Bacher G, Cavalli V, Bevec D, Delgado M, Müller-Quernheim J. Inhaled vasoactive intestinal peptide exerts immunoregulatory effects in sarcoidosis. *Am J Respir Crit Care Med*. 2010;182:540-8
- ¹⁰ Petkov V, Mosgoeller W, Ziesche R, Raderer M, Stiebellehner L, Vonbank K, Funk GC, Hamilton G, Novotny C, Burian B, Block LH. Vasoactive intestinal peptide as a new drug for treatment of primary pulmonary hypertension. *J. Clin. Invest* 2003;111:1339-1346.
- ¹¹ Leuchte HH, Baezner C, Baumgartner RA, et. al. Inhalation of vasoactive intestinal peptide in pulmonary hypertension. *Eur Respir J* 2008;32:1289-1294.
- ¹² Youssef, J.G.; Said, S.; Youssef, G.; Javitt, M.J.; Javitt, J.C. Treatment of Acute Respiratory Distress Syndrome with Vasoactive Intestinal Peptide. *Preprints* 2020, 2020070453 (doi: 10.20944/preprints202007.0453.v1).
- ¹³ Frye BC, Meiss F, von Bubnoff D, Zissel G, Muller-Quernheim J. Vasoactive intestinal peptide in checkpoint inhibitor-induced pneumonitis. *N Engl J Med* 2020;382:26
- ¹⁴ Virgolini I, Kurtaran A, Raderer M, et. al. Vasoactive Intestinal Peptide Receptor Scintigraphy. *J Nucl Med* 1995;36(10):1732-1739
- ¹⁵ Mossel EC, Wang J, Jeffers S, et al. SARS-CoV replicates in primary human alveolar type II cell cultures but not in type I-like cells. *Virology* 2008;372:127-135.
- ¹⁶ Alessandrini, F., Thakkar, M., Foda, H.D., Said, S.I., Lodi, R., Pakbaz, H., and Schraufnagel, D.E. Vasoactive intestinal peptide enhances lung preservation. *Transplantation* 1993;56:964-973
- ¹⁷ Pakbaz H, Berisha H, Sharaf H, Foda HD, Said SI. VIP enhances and nitric oxide synthase inhibitor reduces survival of rat lungs perfused ex vivo. *Ann. N. Y. Acad. Sci.* 1994;723:426-428
- ¹⁸ Li, L., Luo, Z.Q., Zhou, et. al. Effect of vasoactive intestinal peptide on pulmonary surfactants phospholipid synthesis in lung explants. *Acta Pharmacol. Sin.* 2004;25:1652-1658
- ¹⁹ Li L, She H, Yue S, et. al. Role of C-Fos gene in vasoactive intestinal peptide promoted synthesis of pulmonary surfactant phospholipids. *Regul Pept* 2007;140(3):117-124
- ²⁰ Li L, Hua S, Yue S, Luo Z, et. al., Vasoactive intestinal polypeptide induces surfactant protein A expression in AII cells through activation of PKC/c-Fos pathway. *Peptides* 2010;31(11):2016-2051
- ²¹ Onoue S, Ohmori Y, Endo K, Yamada S, Kimura R, Yajima T. Vasoactive intestinal peptide and pituitary adenylate cyclase-activating polypeptide attenuate the cigarette smoke extract-induced apoptotic death of rat alveolar L2 cells. *Eur. J. Biochem.* 2004;271: 1757-1767.

-
- ²² Mathioudakis AG, Chatzimavridou-Grigoriadou V, Evangelopoulou E, Mathioudakis GA. Vasoactive Intestinal Peptide Inhaled Agonists: Potential Role in Respiratory Therapeutics. *Hippokratia* 2013;17(1):12-16
- ²³ Jacobs JP, Stammers AH, St Louis J, et al. Extracorporeal membrane oxygenation in the treatment of severe pulmonary and cardiac compromise in COVID-19: experience with 32 patients. *ASAIO J* 2020; epub ahead of press.